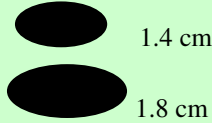


## Dog Embryo/Fetal Development Calendar

<p><b><u>Fertilization:</u></b></p> <p>Germ cells, i.e. sperm and egg fuse together and the phases of mitosis begin. During mitosis genetic information from the parents is merged.</p>	<p><b>96 Hours:</b></p> <p>Divides into two cells.</p>	<p><b>120 Hours:</b></p> <p>Divides into four cells.</p>	<p><b>144 Hours:</b></p> <p>Divides into eight cells.</p>	<p><b>192 Hours:</b></p> <p>The morula is constituted. The morula is a compact mass of 32 cells. In size the mass has grown little.</p>	<p><b>9 Days:</b></p> <p>The morula enters the uterus.</p>	<p><b>15 Days:</b></p> <p>A blastula is constituted. The blastula is a hollow ovule consisting of 500-2000 cells. The blastula is not attached and floats freely within the uterus.</p>
<p><b>18 Days:</b></p> <p>The placenta is developed. The placenta provides oxygen and nutrients to the fetus and takes away waste to be excreted by the mother.</p>	<p><b>20 days:</b></p> <p>The ovule has changed in shape in order to adhere to the wall of the uterus. The nervous system is formed thus organogenesis has begun. Organogenesis is the phase in which all body organs are formed. The nervous system, including the brain and spinal chord are the first organs formed.</p>	<p><b>23 Days:</b></p> <p>The individual ovules have adhered to the walls of the uterus. Swelling occurs at adherence sites. Palpitation may be used for the next few days to determine pregnancy but the method is only accurate 70% of the time. A test for the relaxin hormone can be conducted at this point to determine pregnancy.</p>	<p><b>28 Days:</b></p> <p>The embryo is oval shaped now and measures approx. 1.4 cm to 1.8 cm.</p> <div style="text-align: center;">  </div>	<p><b>30 Days:</b></p> <p>The eyes are formed and covered by eyelids. Sexual organs are apparent.</p>	<p><b>40 Days:</b></p> <p>Swelling of the mother's abdomen may be observed. The swelling is relative to the number of puppies the mother is carrying and the number of previous litters she has had. Abdominal swelling may be less noticeable at this stage for first time mothers.</p>	<p><b>43 Days:</b></p> <p>Heartbeat is detectible by ultrasound.</p>
<p><b>45 Days:</b></p> <p>From this time on the growth of the fetus is accelerated. The mother's appetite will likely increase.</p>	<p><b>51 Days:</b></p> <p>The skeleton of the fetus is calcified and can be seen by x-ray.</p>	<p><b>57 Days:</b></p> <p>The fetus has completed prenatal development and is ready to be born.</p>	<p><b>58 Days:</b></p> <p>Whelping is imminent from this point on.</p>	<p><b>63 Days:</b></p> <p>Considered the normal full term gestation period.</p>	<p>This calendar is meant to be a general guide. It is interesting to note that no visual signs of pregnancy may be seen for almost 2/3rds of the pregnancy. Note the small size of the embryo on day 28.</p>	